NHS Lothian

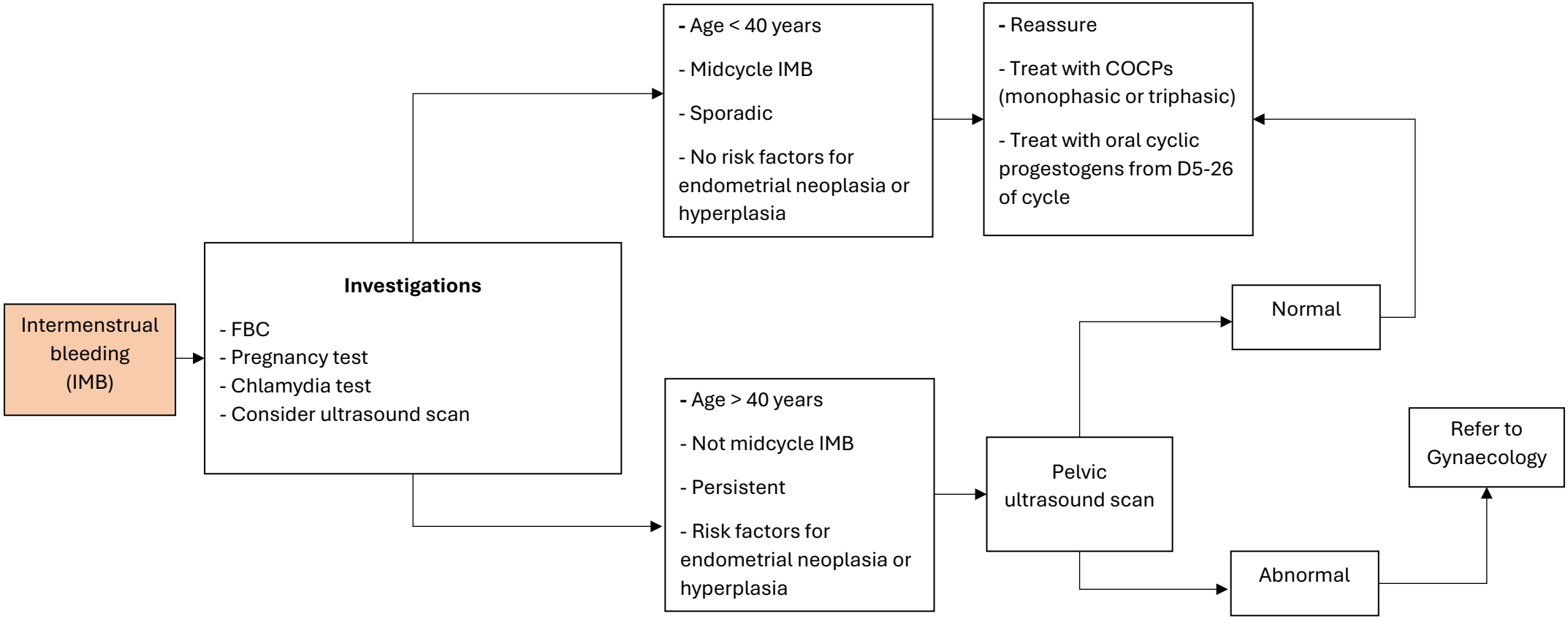
Intermenstrual bleeding (IMB)
Investigations
- FBC
- Pregnancy test
- Chlamydia test
- Consider ultrasound scan
- Age < 40 years
- Midcycle IMB
- Sporadic
- No risk factors for endometrial neoplasia or hyperplasia
- Reassure
- Treat with COCPs (monophasic or triphasic)
- Treat with oral cyclic progestogens from D5-26 of cycle
- Age > 40 years
- Not midcycle IMB
- Persistent
- Risk factors for endometrial neoplasia or hyperplasia
Pelvic ultrasound scan
Normal
Abnormal
Refer to Gynaecology