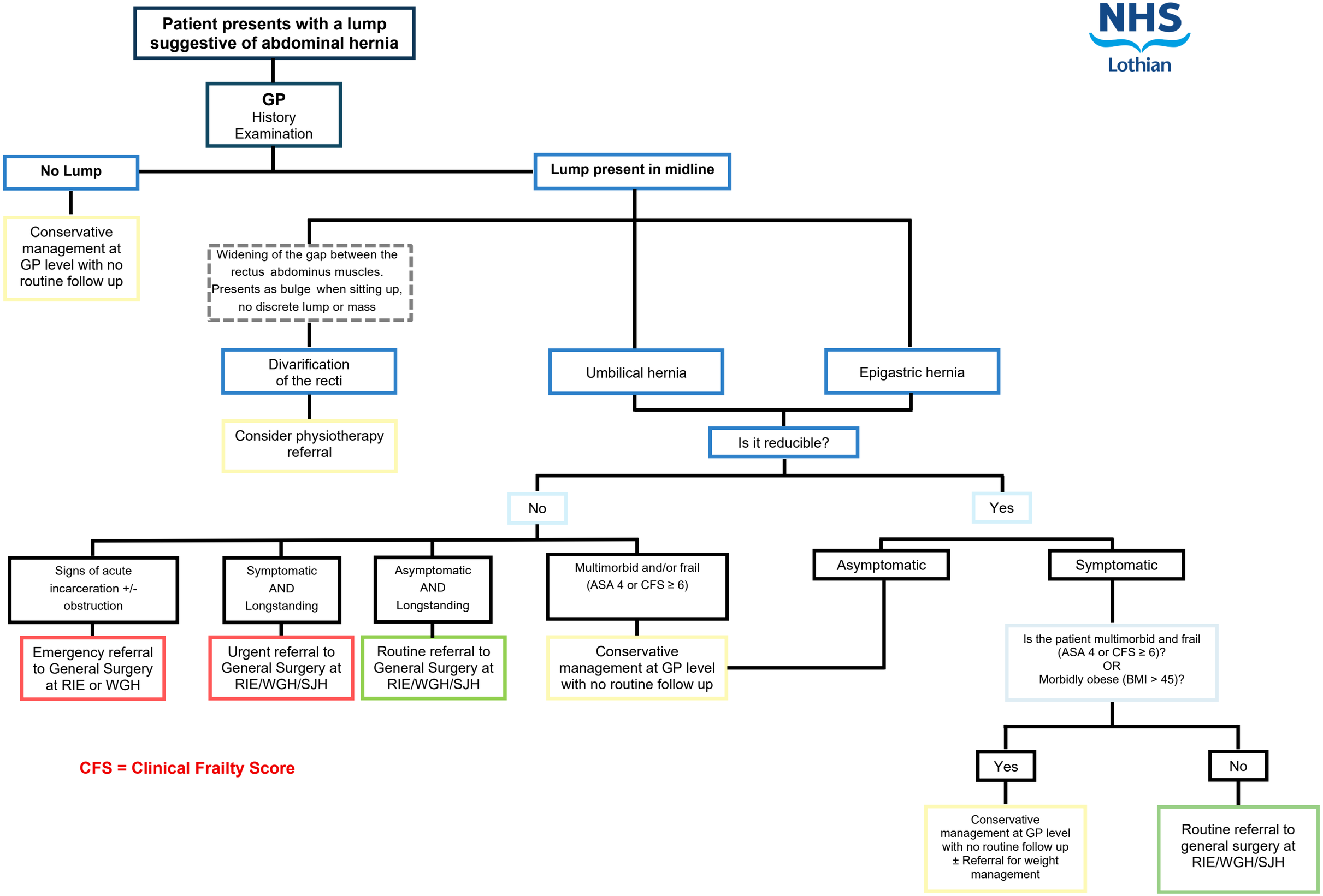
Patient presents with a lump suggestive of abdominal hernia
GP
History
Examination
No Lump
Conservative management at GP level with no routine follow up
Lump present in midline
Widening of the gap between the rectus abdominus muscles. Presents as bulge when sitting up, no discrete lump or mass
Divarification of the recti
Consider physiotherapy referral
Umbilical hernia
Epigastric hernia
Is it reducible?
No
Yes
Signs of acute incarceration +/- obstruction
Emergency referral to General Surgery at RIE or WGH
Symptomatic AND Longstanding
Urgent referral to General Surgery at RIE/WGH/SJH
Asymptomatic AND Longstanding
Routine referral to General Surgery at RIE/WGH/SJH
Multimorbid and/or frail (ASA 4 or CFS ≥ 6)
Conservative management at GP level with no routine follow up
Asymptomatic
Symptomatic
Is the patient multimorbid and frail (ASA 4 or CFS ≥ 6)? OR Morbidly obese (BMI > 45)?
Yes
No
Conservative management at GP level with no routine follow up ± Referral for weight management
Routine referral to general surgery at RIE/WGH/SJH
CFS = Clinical Frailty Score