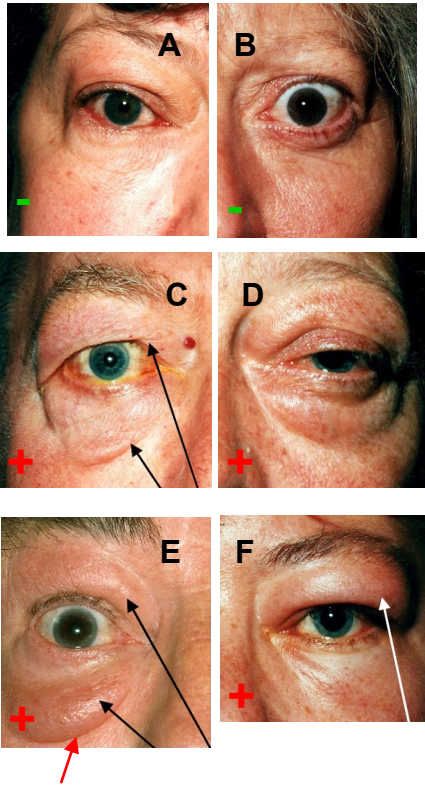


Clinical activity score in Graves' Ophthalmopathy

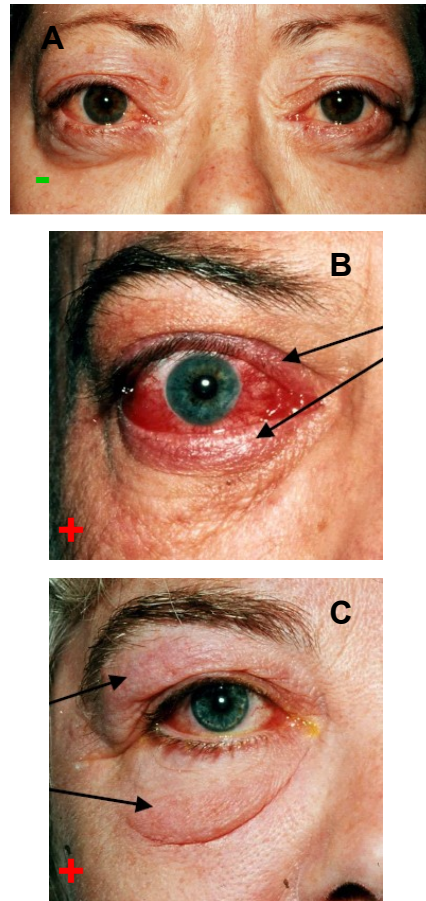
Scoring guide

EYELID SWELLING



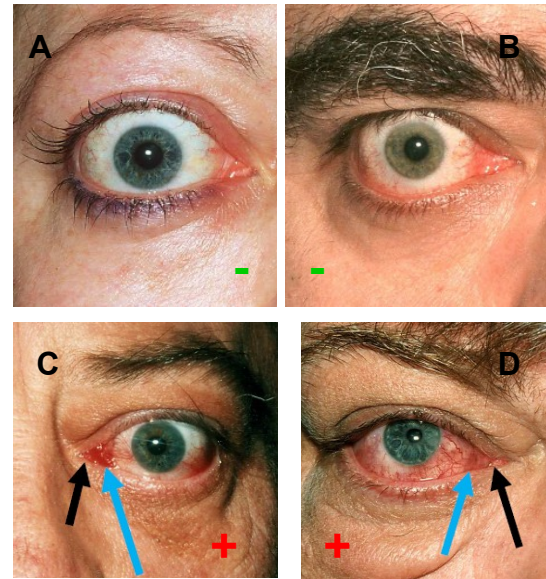
A&B. Mild CAS 0.
C&D. Moderate CAS 1.
Subcutaneous fluid (black arrows) or skin thickening (white arrows)
E&F. Severe CAS 1.
Tense subcutaneous fluid or skin thickening. Swelling in lower lid forms a festoon (red arrow)

EYELID ERYTHEMA



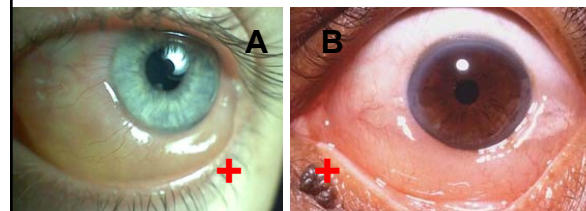
A. Normal CAS 0.
B. Pretarsal erythema CAS 1.
C. Preseptal erythema CAS 1.

CONJUNCTIVAL REDNESS



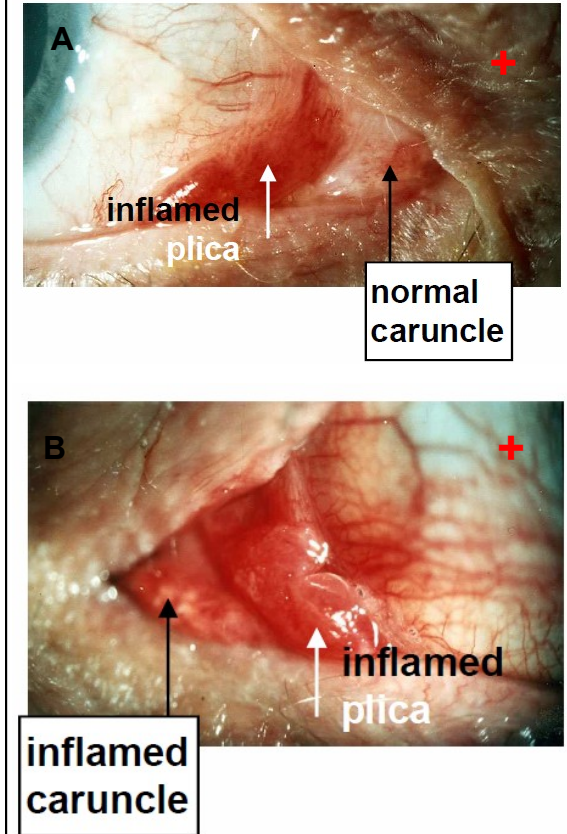
A. Normal CAS 0. **B.** Equivocal/Mild CAS 0.
C. Moderate <50% redness excluding plica and caruncle CAS 1.
D. Severe >50% redness excluding plica and caruncle CAS 1.

CHEMOSIS



A & B. Chemosis CAS 1.

CARUNCLE AND PLICAL INFLAMMATION



A & B. Inflamed plica or caruncle CAS 1. Plica prolapses through closed eyelid CAS 1.